DIAGNOSIS OF GLAUCOMA

To definitely say that a person has glaucoma requires several tests, and many times these need to be repeated over time before confirming the diagnosis.

a. **Intraocular Pressure:** This is the pressure within the eyeball, which is usually 10-21 mm Hg. It can be measured by several different techniques. Sometimes a single recording cannot confirm or rule out diagnosis of glaucoma, in which case it needs to be repeated. In all individuals the pressure within the eye is not constant throughout the day, there is normally a variation. Hence sometimes it may be necessary to record the intraocular pressure at different times of the day.

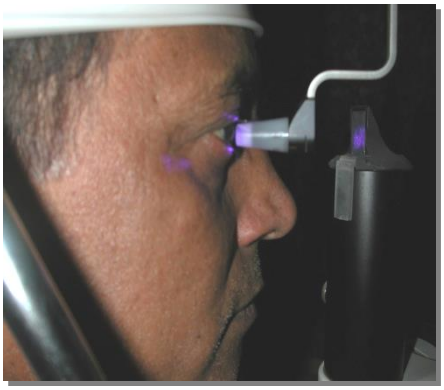

b. **Gonioscopy:** This is a test by which the drainage area, from where the aqueous fluid from the eye is drained, is examined by a special lens. This area is known as the *'angle'*. In case some abnormality is found in the angle, steps can be taken to correct the defect, and restore normal fluid circulation in the globe. In young child suspected with glaucoma, we need to perform this test in operation theater under anesthesia.

Using this lens, we differentiate between open angle and closed angle

c. **Pachymetry:** This is a test to evaluate the central corneal thickness. This may influence the recording of pressure within the eyeball.

d. **<u>Perimetry:</u>** This is a test to evaluate the field of vision. It is conducted on a computerized machine, which is able to pick-up even subtle defects. The tests have to be repeated periodically, before a clear interpretation can be drawn. Repeat tests are also necessary to pick up any deterioration, so that timely treatment may be given.

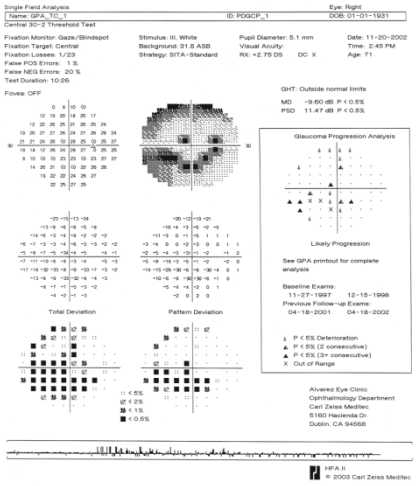

e. **<u>Photography of the Optic Nerve:</u>** The optic nerve can be photographed with a Fundus Camera. This serves as a permanent record and would help pick-up changes early. In subsequent visits repeat photographs are taken which can be compared with the earlier ones.

f. **<u>Optical Coherence Tomography (OCT):</u>** It is a recent diagnostic imaging technique that can perform very high resolution (in micro millimeters) cross-sectional imaging of in biological tissues. It is a non-invasive, non-contact imaging technology similar to ultrasound but has considerably greater resolution. It allows detailed examination of the retinal nerve fiber layer (RNFL), macular area in the retina and optic nerve head.

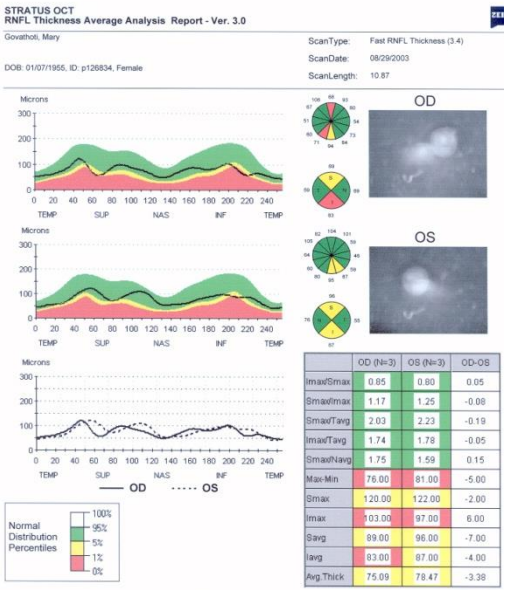

g. <u>HRT III (Heidelberg Retinal Tomogram):</u> It is an imaging tool that calculates the three-dimensional surface topography of the optic disc region. This calculation is based on a series of images obtained using a laser. Software in the HRT III provides the user with a number of quantitative parameters of the optic nerve head and also several inbuilt diagnostic indices to help the doctor in the diagnosis of glaucoma.

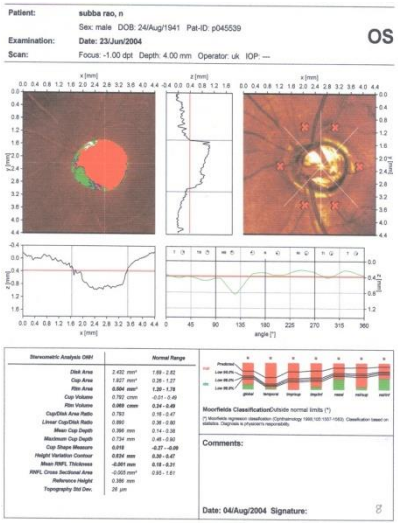

h. <u>Scanning Laser Polarimetry (GDx VCC):</u> It is a recently developed non-invasive imaging technique for measuring the RNFL thickness. The laser beam is passed through the retinal nerve fiber layer twice and the software in the machine provides numerical values, which can help to predict the likelihood of the patient having glaucoma.



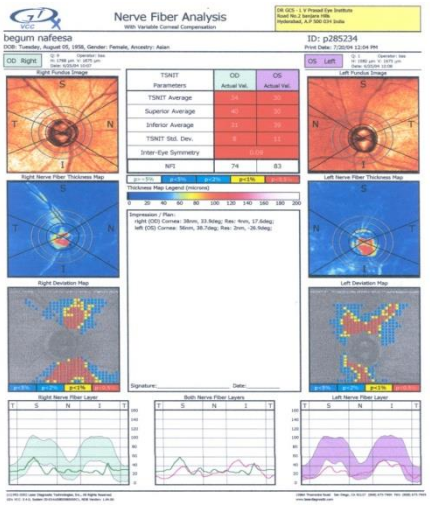

i. **<u>Anterior Segment OCT (Visante OCT):</u>** It is a latest addition in glaucoma management. It is a new optical coherence tomography anterior segment scanner, which uses infrared light to visualize a "slice" through the anterior chamber. It is useful for the assessment of narrow angles and measuring anterior chamber width. The Visante OCT is non-contact.

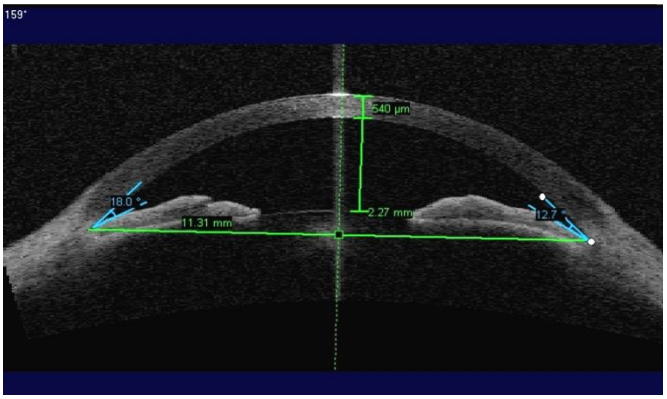

Each technology has unique applications. These devices currently cannot replace visual field testing but serve as to complement it in the comprehensive monitoring of patients with glaucoma. Some of this technology is better in regard to early diagnosis and another technology better in providing superior detection of worsening of the disease. Hence a compendium of these diagnostic tools along with visual field testing is the better way to go in the management and follow-up of glaucoma.

HOW IS GLAUCOMA DIAGNOSED?

The diagnosis (or exclusion) of glaucoma requires a detailed, comprehensive examination of the eye. Your doctor will do the following examinations:

1. A routine vision test that requires reading letters from a chart

2. Slit lamp (microscope) examination

3. Measurement of the pressure in the eye usually using the applanation tonometer attached to the slit-lamp microscope. A hand held version of the same instrument is acceptable. It may be necessary to obtain multiple readings of the pressure during the course of the day and night.

4. Examination of the angle of the eye using a gonioscope. Steps 3 and 4 require the use of a drop to eliminate the sensation in the eye. The drop may burn a little bit.

Drops in the eye to dilate the pupil to facilitate:

5. Examination of the optic disc and the back of the eye (retina). Obtaining a stereoscopic view on the microscope using a hand held lens is the best method.

6. Newer computerized methods of examining the optic disc as shown above may be ordered. This is literally a computerized scan of the optic disc.

7. If glaucoma is suspected, then to confirm the diagnosis, the doctor will obtain an automated field test (perimetry test). Some patients may have difficulty doing this test for the first time. It may also be necessary to obtain several such tests as a baseline for future comparison. Considering the importance of the test ANY automated perimeter is

NOT acceptable. The field test (perimetry) is a subjective test and it is important to have a calibrated machine with an appropriate normal database against which to compare your results.

In some cases a diagnosis may not be possible on one visit. In very early cases it may be necessary to repeat the entire examination after a period of observation.